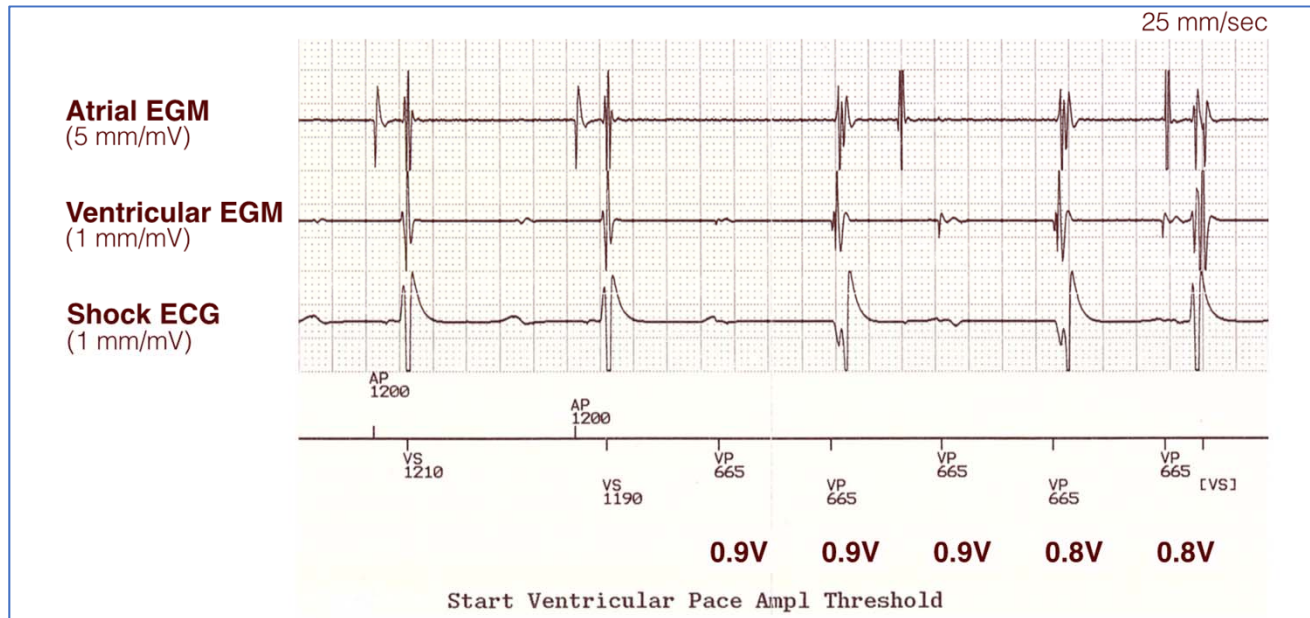


Circulation: Arrhythmia and Electrophysiology – CHALLENGE OF THE WEEK

A young patient with long QT syndrome and history of recurrent syncope comes for routine follow-up on implanted dual-chamber cardioverter-defibrillator. A device tracing from ventricular pace capture test is shown in the Figure. Which of the following statements is true?

Figure. Dual-chamber implanted cardioverter-defibrillator tracings from start of ventricular pacing threshold test. ECG, electrocardiogram; EGM, electrogram.



Answer Options:

- A. The ventricular capture threshold is ≥ 1.0 V.
- B. The ventricular capture threshold is 0.9 V.
- C. The ventricular capture threshold is ≤ 0.8 V.
- D. Retrograde ventriculoatrial conduction is present.
- E. None of the above statements can be inferred.