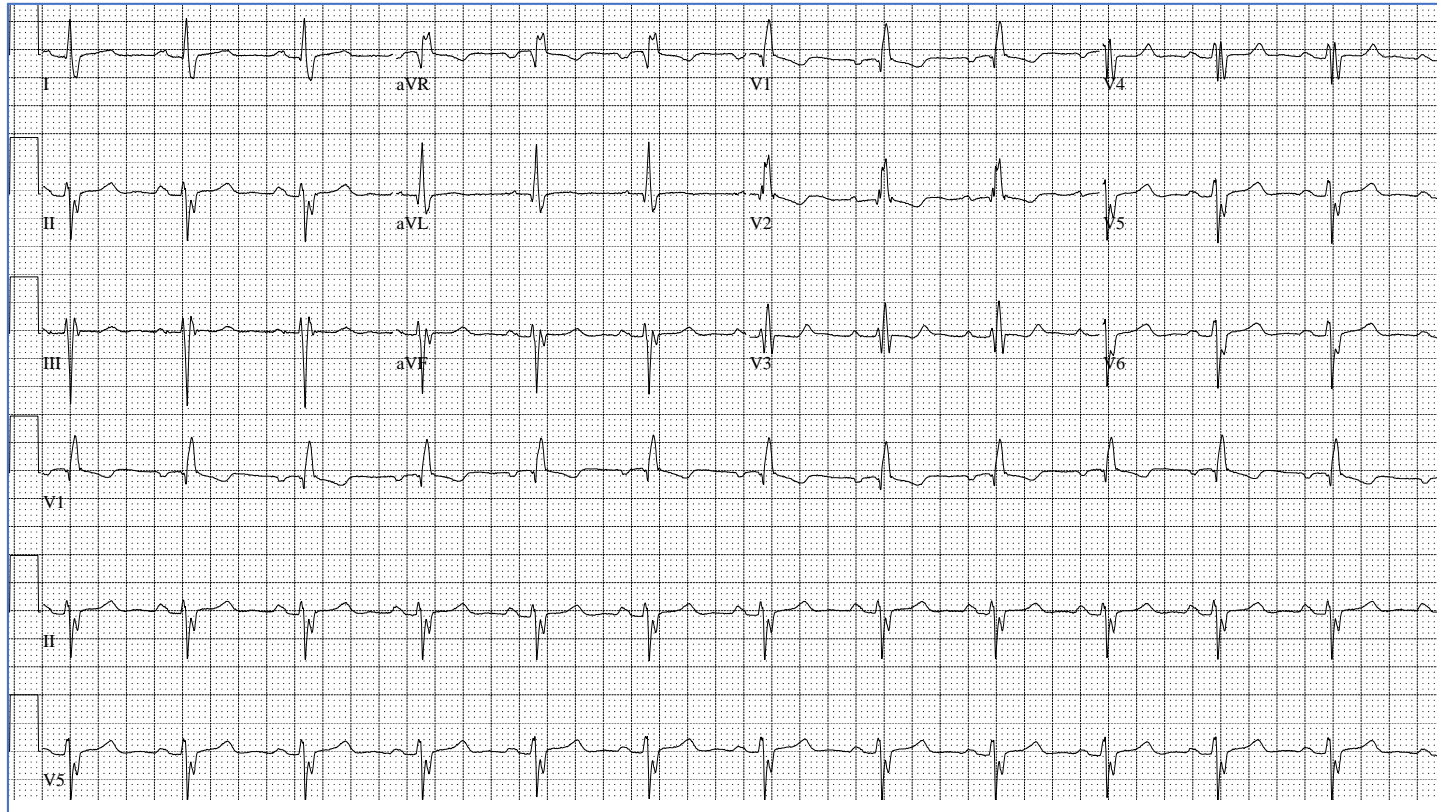


## Circulation: Arrhythmia and Electrophysiology – CHALLENGE OF THE WEEK

A 25-year-old otherwise healthy pregnant woman had complained of periodic palpitations, anxiety, and exertional dyspnea. Her electrocardiogram is shown in the Figure. What is the diagnosis?

**Figure. Twelve-lead electrocardiogram.**



**Answer Options:**

- A. Congenitally corrected transposition of great arteries (S, L, L)
- B. Atrial septal defect

- C. Tetralogy of Fallot
- D. Arrhythmogenic cardiomyopathy
- E. Brugada syndrome